

Monolithisches Abutment, Teil 1

1 The Zeramex product family



Author

ZTM/MDT Wolfgang Weisser

CTB-Circle

Fuchswasenstraße 11

73457 Essingen

Mail wolfgang.weisser@web.de



Autor

Klaus Pettinger

Göppingen

Mail klaus.pettinger@zeramex.com

Klaus Pettinger and Wolfgang Weisser want to motivate their dental technician colleagues to produce individual abutments. It's worth it, say the two dental technicians. In their two-part article, they show why.

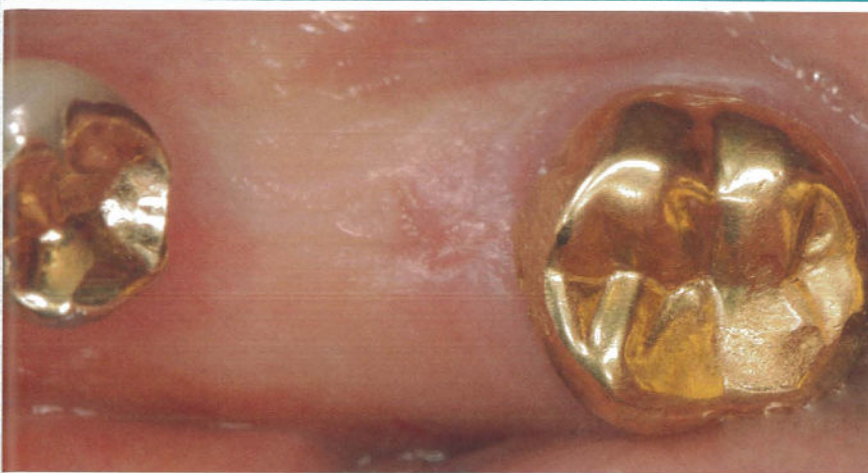The authors have been in the business for a long time – and more: They have many years of experience with implant-supported dentures. Both specialists have made ceramic implants their great passion (Fig. 1). Klaus Pettinger is even one of the pioneers in this area. Wolfgang Weisser was able to benefit from his specialist knowledge. Together they plan and discuss the i :: ifter about the handling and pitfalls of ceramic implants. As a result, the idea arose to describe the procedure of the monolithic abutment step by step in a specialist article.

The patient case

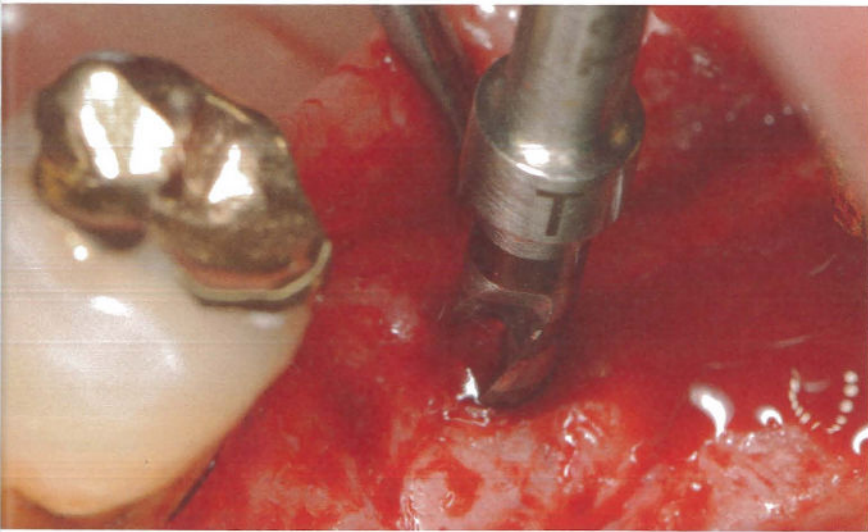
The loss of the tooth in region 36 (Fig. 2) had caused the patient some inconvenience: food particles accumulated in this area

which the man found very annoying. He came to the practice of Dr. Michael Schneider in Schomdorf with the wish to close this gap.

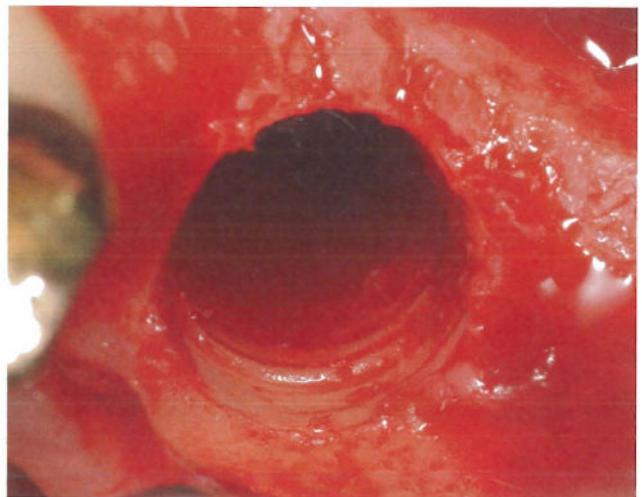
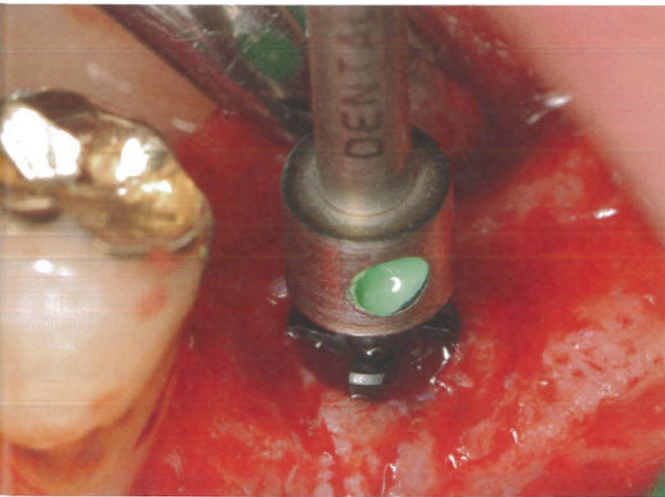
After a detailed diagnosis by the practitioner, it was agreed to insert a cervical implant and to remove all metal restorations from the lower jaw in this treatment phase. The renovation should be done with metal-free reconstructions. The surgical procedure The initial situation shows the opening for displaying the bone – performed with a pilot hole (A) with the Zeradrill Pilot 2.3 mm and then via the EP drill with the Zeradrill W10 with a 5.5 mm drill in preparation for thread cutting (Fig. 3).



2 Initial Situation

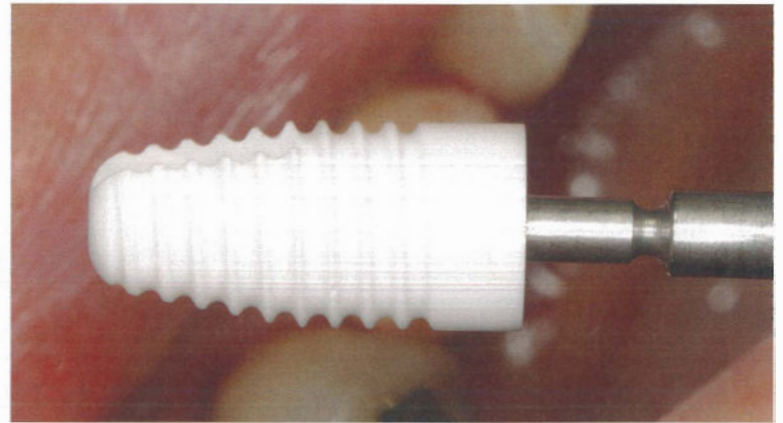


3 Zeradrill Pilot hole \varnothing 2,3 mm

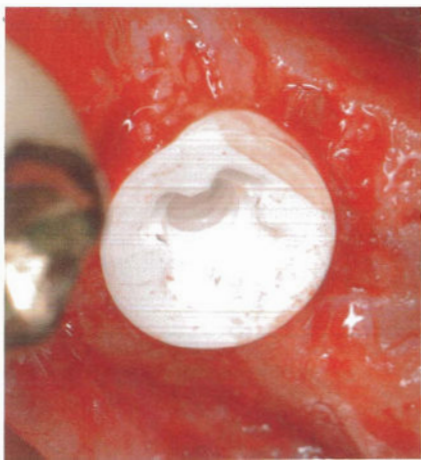


4 Extension drilling
 \varnothing 4,2 mm and \varnothing 5,5 mm
5 Thread cut with Zeratap
 wide \varnothing 5,5 mm

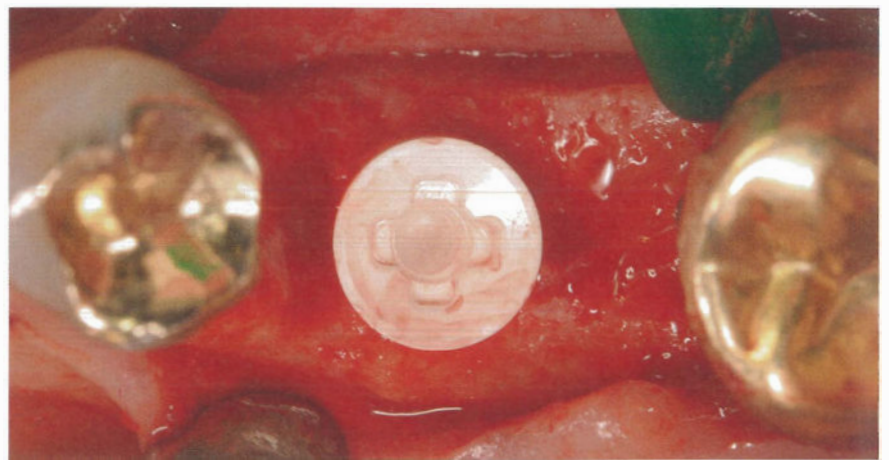
Then the thread cutting protocol followed. With this arrangement, Zeratap wide with 5.5 mm (Fig. Step, everything for inserting the **4** and **5**) is prepared after the surgical implant.



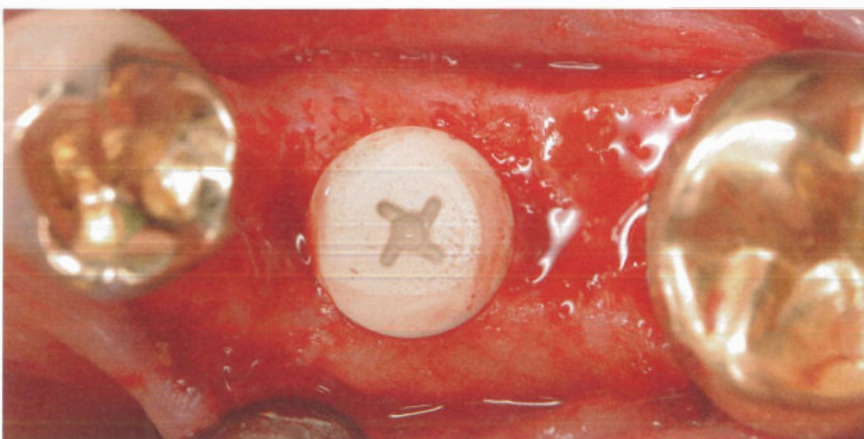
6 and 7 XT 17510 on Pickup



8 Supracrestal set



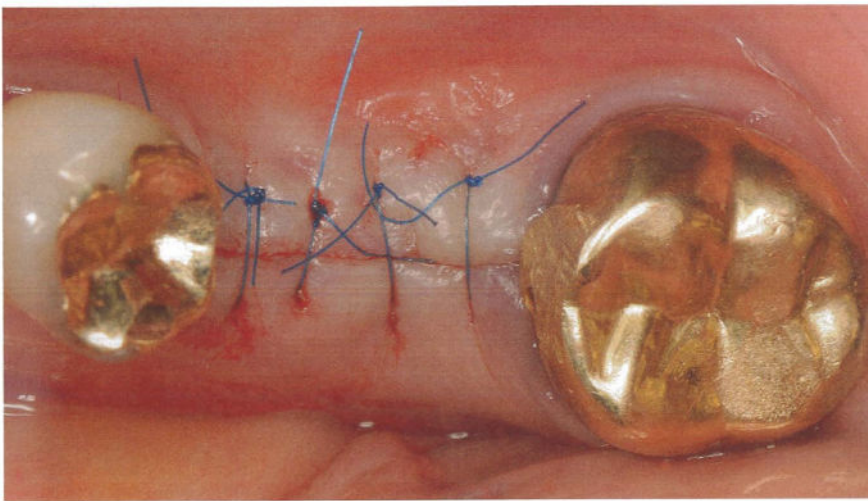
9 Perfectly aligned retention exposure



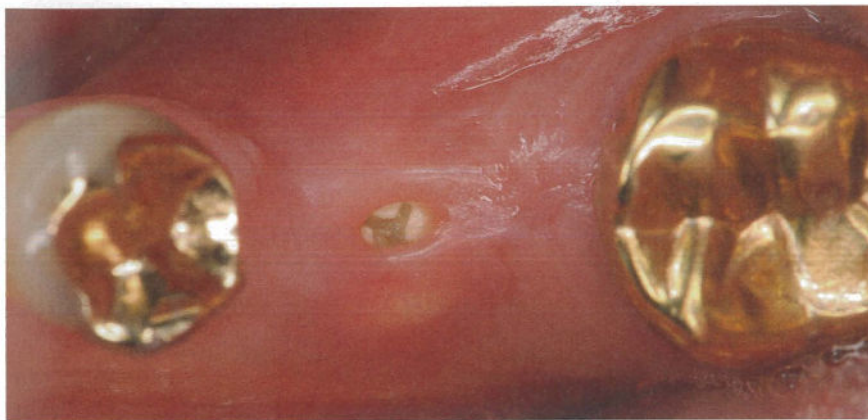10 Closure with Healing Cap WB37500

the XT from ZerameX supracrestal (Fig. **8**) decided. If the retention holder is perfectly aligned, angled standard abutments can later be used in the restoration (Fig. **9**). You can clearly see the concave platform - a ten degree cone. After inserting the XT 17510, the wound is closed with the Healing Cap WB 37500 (Fig. **10**) - with a Dr. Tailors preferred thin sutures (Fig. **11**), which are very comfortable for the patient. After the healing phase, a slightly fenestrated gingiva can be seen over the healing cap (Fig. **12**).

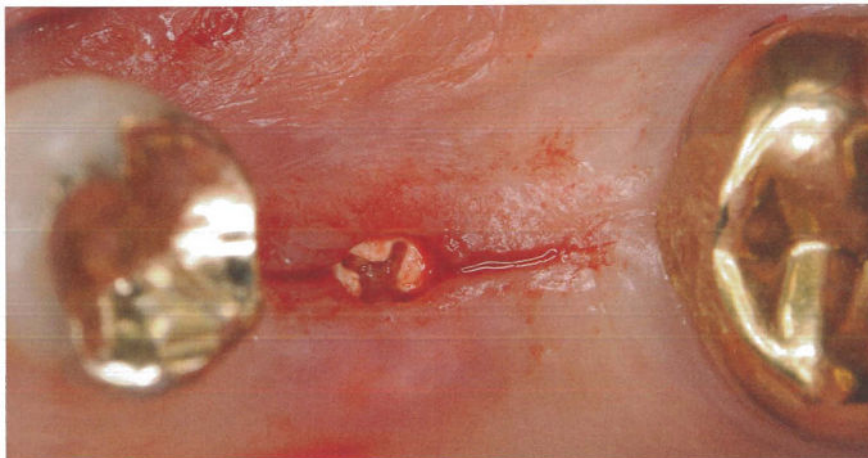
With the pick-up (Fig. **6** and **7**) the wide implant is 10 mm long, Diameter 5.5 mm, used, Dr. Micheal Schneider always sets the same bon level, which is why he is also for



11 Wound closure with thin sutures



12 Slightly fenestrated gingiva upper healing cap

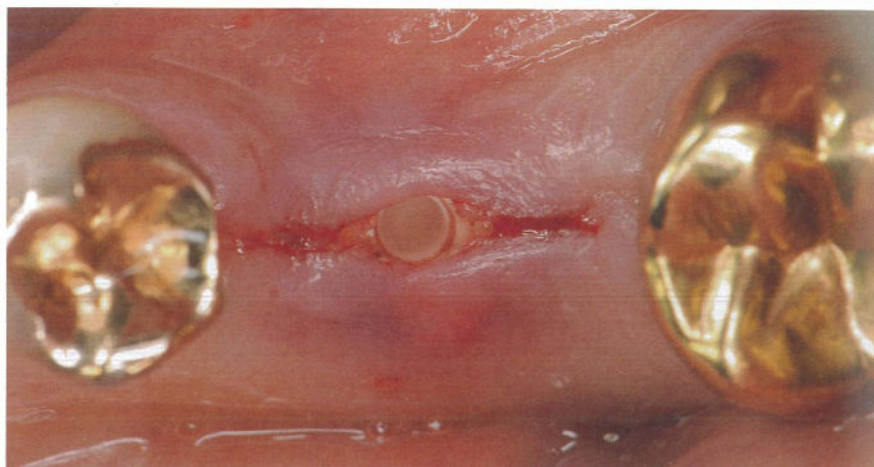


13 Opening incision for placing the healing abutment


The opening is made through the gingiva former (Fig. 13). The practitioner removes the healing cap (Fig. 14), the implant is cleaned and replaced with the healing cap WB 37503

(Fig. 15). You can see the situation very well (Fig. 16). It would also be possible to create a custom healing abutment to prepare the space for the later custom abutment.

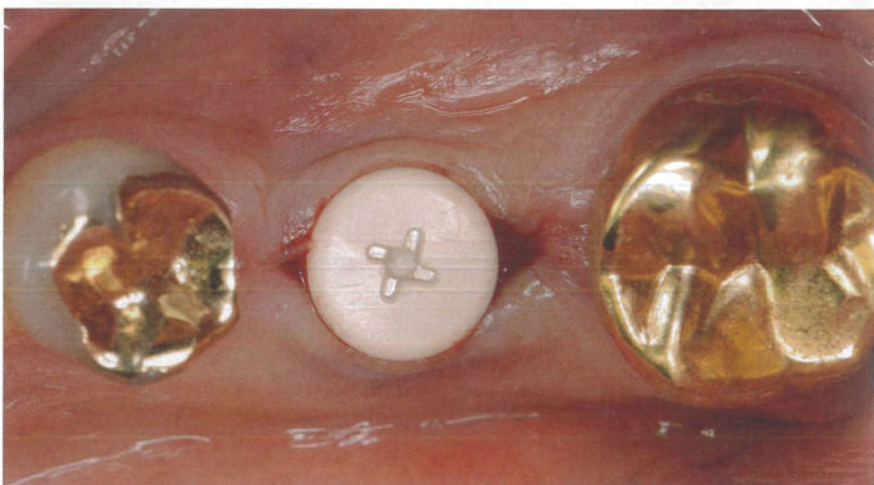
14 Removed healing cap



15 Gingivaformer WB37503



16 Inserted healing abutment



The second part of the article is about taking an impression and inserting the individual abutment.

You can read the continuation in the September issue